

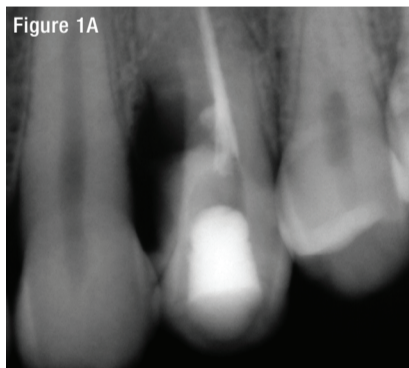
Superior aesthetics with implant restorations

Dr Olivier Benhamou demonstrates through a clinical case study why he only uses tissue-level implants with a zirconia collar...

A 29-year-old male patient was presented to the practice after experiencing toothache in the upper left quadrant of his mouth. This case was unusual in that the patient had a supernumerary tooth located near the upper left 4. The patient admitted to consuming recreational drugs, which triggered him to react by grinding heavily on his teeth. He attended the practice two days later to have an examination and it was found that the supernumerary tooth had fractured from the crown to the root, so an extraction was required. As the patient lacked sufficient bone following this, and in order to protect the upper left 4, a graft was performed using a synthetic bone substitute material.

During the healing of the extraction site, the patient complained of persistent pain in the upper left 4. In an attempt to save the tooth, endodontic treatment was carried out (Figure 1A). However, this proved to be unsuccessful. Further treatment options were discussed with the patient and a treatment plan was formulated, involving extraction of the upper left 4 and the placement of a dental implant.

Figure 1A



After extraction of both the supernumerary tooth and the upper left 4, radiographs (Figure 1B and 1C) were taken to ensure that the bone graft had healed well. These also showed that there was limited bone height available and so an 8mm long TBR Z1 implant (the shortest in the range) was selected. A 5mm diameter was chosen in order to increase the BIC (Bone to Implant Contact) surface. The use of a soft tissue-level implant results in a more favourable crown-to-implant length ratio, as the 1.5mm height of the zirconia collar is considered part of the overall implant length.

Figures 2A and 2B reveal that the tissue had healed and the patient's plaque control was good. In order to protect the existing papilla on the facial side, a single incision was made on the palatal aspect of the gingiva, following an injection of local anaesthetic. Instruments and sutures were used to open the incision and raise the flap where, upon inspection, it was confirmed that the bone graft had indeed been successful (Figure 3).

The surgical site was cleaned before a hole was drilled for the implant (Figures 4A and 4B). As seen, the implant (Figure 5) was placed successfully (Figures 6A and 6B) and

Figure 1B

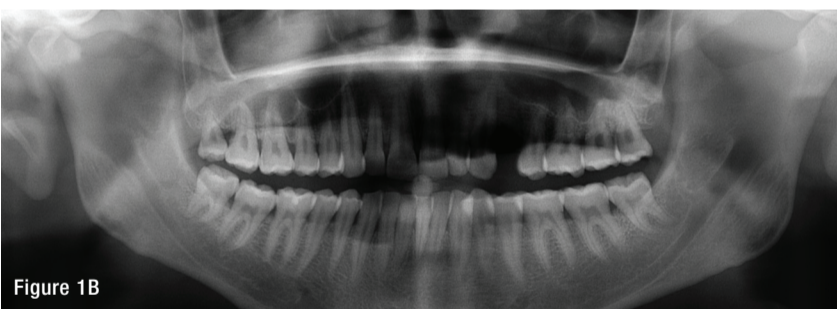
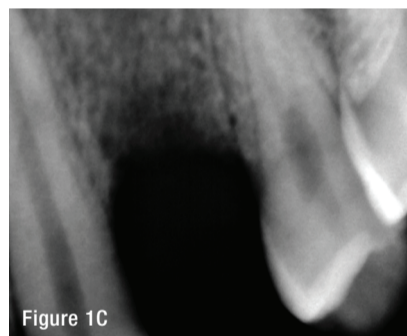


Figure 1C



achieved primary anchorage. The zirconia collar created a good emergence profile and protected the crestal bone (Figure 7). Only two resorbable stitches were required to close the flap (Figure 8) and the cover screw was used to hold everything in place. The patient was given anti-inflammatories and antibiotics to aid in the healing process and prevent infection.

Ten days post-surgery, the implant was reviewed. Figure 9 shows that the gingiva around the implant was pink with no inflammation, indicating that it was healthy and had healed well. The natural papilla had started to reveal itself as well, further increasing the chance of an optimum aesthetic result.

Three months after implant placement, the TBR Swiss Clip impression coping was used (Figure 10) to take an impression. This is a quick and easy alternative to traditional impression copings that must be screwed

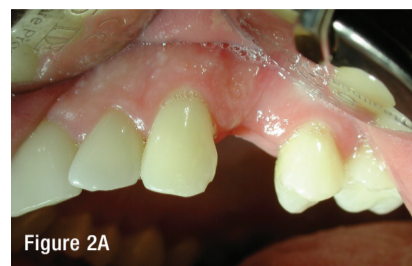

Figure 2A

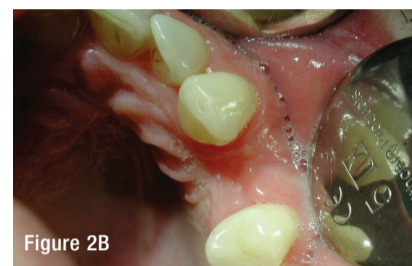

Figure 2B

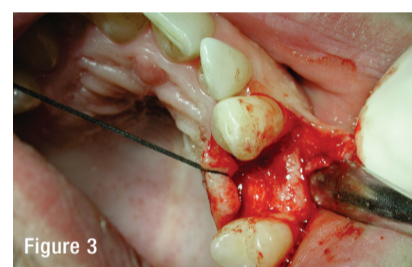


Figure 3

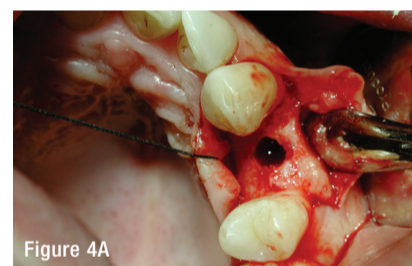


Figure 4A

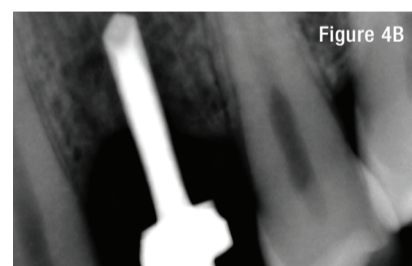


Figure 4B

READER ENQUIRY NO: 48







THE WAY TO COMFORT

onto the implant, which is a time-consuming and cumbersome process.

The impression was then sent to the laboratory in order to create a bespoke metal ceramic crown. For this patient, I preferred to use a metal ceramic crown because it combines the benefits of the metal's mechanical features, with the supreme aesthetic qualities of the ceramic. The abutment and crown were then fitted

to the implant with cement (Figures 11 and 12). I always use cement for single-unit implant restorations because it offers greater aesthetics and is also reliable. Ultimately, it is up to the practitioner to decide whether to use cement- or screw-retained restorations. In this case, using cement is appropriate because the soft tissue adheres to the zirconia collar of the Z1 implant, so there is no potential for the cement to infiltrate between the implant and the gum – which could lead to inflammation and failure of the implant.

Before the patient was released, the function of the implant-retained crown was examined and a couple of minutes were spent checking the occlusion to ensure that there were no occlusal and lateral interferences.

The patient was very happy with the overall result. He was advised to avoid grinding his teeth again and to maintain good oral hygiene in order to avoid any complications in the future. He remains a regular patient to the practice and his implant is reviewed twice a year during routine check-ups.

Reflection

As a young patient, achieving an aesthetic result was of vital importance in this case. Figure 12 shows that the soft tissue around the implant was healthy, with no black

triangles between the teeth. You cannot tell any difference between the implant restoration and the surrounding natural teeth. The zirconia collar of the Z1 implant enhances aesthetics as it eliminates the chances of the grey metallic component becoming visible through the soft tissue. It also protects the periodontium, which promotes better soft tissue management.

The TBR Z1 is my gold standard implant

choice, as it eliminates the problems previously encountered with traditional implant solutions. The design and engineering of the Z1 implant can ensure long-term, aesthetic results, and greater comfort for both the clinician and the patient. For more information visit www.dental-express.co.uk. ■

About the author

Dr Olivier Benhamou is a doctor of dental surgery and a specialist in periodontology, with an interest in implant dentistry. He practices in Brussels and is part of TBR's expert training team.

